

Monkeypox virus Infection

What is the monkeypox virus?



Monkeypox virus or MPV is a rare disease caused by orthopoxvirus genus.

Fast Facts

INCUBATION PERIOD

Approximately **7-14** days

Early Symptoms:



HEADACHE



FEVER



SWOLLEN LYMPH NODES



EXHAUSTION



BACKACHE

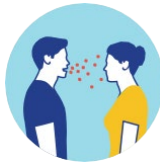


CHILLS

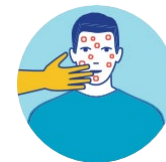

MUSCLE ACHES

SPREAD



Respiratory secretions or droplets during prolonged (>3 hours of unmasked contact), face-to-face or skin-to-skin contact, or during intimate physical contact, such as kissing, cuddling, or sex.



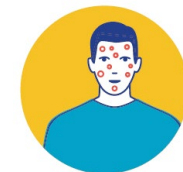Direct contact with the infectious rash, scabs, or body fluids.



Touching items (such as clothing or linens) that previously touched the infectious rash or body fluids.



Pregnant people can spread the virus to their fetus through the placenta.



Possible Rash Locations (Following early symptoms)

Palms of hands and soles of the feet, face, genitalia, face, oral mucous membranes, cornea, and conjunctivae.

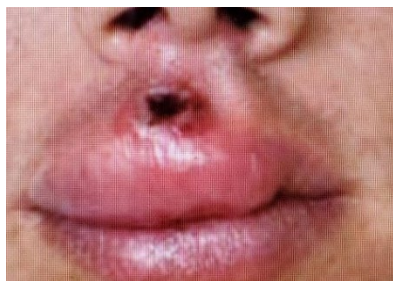Stage	Stage Duration	Characteristics of MPV Rash
Enanthem		The first lesions to develop are on the tongue and in the mouth.
Macules	1-2 days	The rash typically spreads to all parts of the body within 24 hours.
Papules	1-2 days	By the third day of the rash, lesions have progressed from macular (flat) to papular (raised).
Vesicles	1-2 days	By the fourth to fifth day, lesions have become vesicular (raised and filled with clear fluid).
Pustules	5-7 days	By the sixth to the seventh day, lesions have become pustular (filled with opaque fluid - sharply raised, usually round and firm to the touch).
Scabs	7-14 days	By the end of the second week, pustules have crusted and scabbed over. Scabs will remain for about a week before beginning to fall off.

Once all scabs have fallen off, a person is no longer contagious.

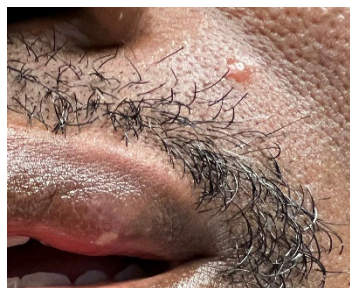MPV considerations for Oral Health Providers

Aerosol-generating procedures on MPV-infected patients can put oral health personnel at risk of contracting the disease. When a suspected MPV lesion has been identified, non-urgent aerosol-generating procedures should be deferred until the area is healed. Below is more information on monkeypox and how to identify its oral manifestations.

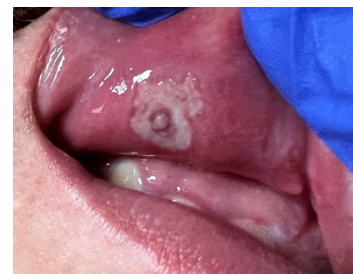- Obtain patients' history (any skin contact with similar lesions, travel history, sexual history).
- Stay informed about cases in your community.
- Question patients about close contact with persons suspected or confirmed with monkeypox.
- Lesions/ulcers/scabs in the oral cavity may present as herpes, syphilis, and varicella, in addition to monkeypox, and should be considered in the differential diagnosis.
- Examine submandibular/cervical lymph nodes for any enlargements.
- Rash may first appear on the face with intra-oral lesions before spreading to other parts.
- Lesion can look like a pimple with a flat base, be deep-seated, and may be painful depending on location.
- If facial or oral lesions are distinguished, or suspicious of monkeypox, verify with the Illinois Department of Public Health (IDPH), your [local health department](#) or Centers for Disease Control and Prevention (CDC) recommended epidemiological criteria for suspected monkeypox cases.



MVP Lesion, upper lip
Courtesy of C. Creticos, MD



MVP Lesion, upper lip, face
Courtesy of V. Chundi, MD



Intraoral MVP Lesion
Courtesy of V. Chundi, MD

Prevention of Spread

- | | |
|---|--|
| Early detection | Stringent cleaning protocols |
| Early recognition | If a lesion is in the mouth, wear a mask to protect others |
| Isolation | Proper hand hygiene |
| Proper personal protective equipment (PPE) use and doffing procedures | |
| | Notify your local health department |

Resources

- <https://dph.illinois.gov/monkeypox.html>
- <https://dph.illinois.gov/monkeypox/about-mpv.html>
- <https://www.cdc.gov/poxvirus/monkeypox/index.html>
- <https://www.who.int/news-room/fact-sheets/detail/monkeypox>
- [How it Spreads | Monkeypox | Poxvirus | CDC](https://www.cdc.gov/poxvirus/monkeypox/symptoms.html)<https://www.cdc.gov/poxvirus/monkeypox/symptoms.html>
- Peters SM, Hill NB, Halepas S, Oral manifestations of monkeypox: A report of two cases Journal of Oral and Maxillofacial Surgery (2022), doi: <https://doi.org/10.1016/j.joms.2022.07.147>